

# BALLOON SINUPLASTY WITH USE OF INTRA-OPERATIVE NAVIGATION IN CHILDREN – PRELIMINARY REPORT

\*Lechosław P. Chmielik<sup>1</sup>, Jolanta Jadczyzyn<sup>1</sup>, Magdalena Frąckiewicz<sup>1</sup>, Anna Chmielik<sup>2</sup>, Romana Bogusławska<sup>2</sup>, Mieczysław Chmielik<sup>1</sup>

<sup>1</sup>Department of Paediatric Otorhinolaryngology, Medical University of Warsaw, Poland  
Head of Department: Prof. Mieczysław Chmielik, MD, PhD

<sup>2</sup>Medical Radiology Unit. Military Medical Institute, Warsaw, Poland  
Head of Radiology Unit.: Ass. Prof. Romana Bogusławska, MD

---

## Summary

**Introduction.** Since eighties a dynamic development of sinus surgical techniques has started. In the beginning the functional endoscopic sinus surgeries were introduced in adults. With gaining experience this technique with modifications was also introduced in children as pediatric endoscopic sinus surgery. Most authors in publications state that stenosis of natural ostium of sinuses is one of the main causes of chronic rhinosinusitis. For this reason further researches went in the direction of minimalization of intra-operative trauma and increasing precision of surgeries. In 2005 and 2006 there were first reports about using balloon sinuplasty. This technique is based on introducing a balloon in the natural ostium of sinus and extending the balloon. Due to identify the localization of balloon C arm or fluorescence are used.

**Aim.** Due to better intra-operative orientation and decreasing the dose of X radiation in the intra-operative period authors were using intra-operative navigation during balloon sinuplasty.

**Material and methods.** Between 2009 and 2010 in the Pediatric Otolaryngology Clinic authors conducted 10 operations with use of balloon sinuplasty and intra-operative navigation. During operation data of guide catheter were introduced to navigation to gain a possibility of intra-operative navigation. To navigate standard instruments were used. Then through sinus guide catheter the optic fibre-sinus illumination was introduced. This system was a guide and enabled the fluorescence of sinus. At then the Balloon Catheter was introduced and the ostium was widened. With the use of navigation the localization of guide catheter was determined and with use of standard instruments localization of balloon was determined.

**Conclusions.** 1. Balloon sinuplasty seems to be optimal method of treatment for children with stenosis of natural ostia of sinus and limited mucous lesions. 2. Intra-operative navigation enables to gain better orientation in operating area when using balloon sinuplasty and to decrease the dose of X radiation in the peri-operative period. 3. The use of navigation with standard instruments gives minor measuring error than the use of navigation with instruments additionally introduced into the system.

---

Key words: Balloon sinuplasty, intra-operative navigation, chronic rhinosinusitis, children

---

## INTRODUCTION

Since the eighties we have seen a dynamic development in sinus surgical techniques. In the beginning, functional endoscopic sinus surgery was introduced for adults (1-3). With increasing experience, this technique (with modifications) was also introduced for children as paediatric endoscopic sinus surgery (4-6). Most authors state in their publications that stenosis of the natural ostium of the sinuses is one of the main causes of chronic rhinosinusitis. For this reason, further research went in the direction of minimalising intra-operative trauma, and increasing the precision of surgery. The first reports on the use of balloon sinuplasty appeared in 2005-2006 (7). This technique is based on introducing a balloon into the natural ostium of the sinus, and then extending the balloon. In order to fix the location of the balloon, C arm and illumination are used. The navigation can operate on the optical or electromagnetic principle.

## AIM

The aim of the research was to evaluate the possibility of better intra-operative orientation with a decreased dose of X-rays. The authors have used intra-operative navigation during balloon sinuplasty. This basis we estimated of clinical results gained with this method.

## MATERIAL AND METHODS

Between 2009 and 2010 in the Department of Paediatric Otolaryngology, the authors conducted 10 operations balloon sinuplasty and intra-operative navigation. All patients had an up-to-date computed tomography of the sinuses. The criterion for inclusion was chronic or recurrent rhinosinusitis that lasted longer than 12 weeks, with stenosis of the natural ostium, during remission after antibiotic treatment with limited mucous lesions. The criterion for exclusion was acute rhinosinusitis, chronic rhinosinusitis with polyps, or extensive inflammatory le-

Table 1. Results of measuring errors with use of optic navigation.

No.	Nasal tip – standard instrument – measuring error in mm	Medial angle of the eye – standard instrument – measuring error in mm	Anterior edge of middle nasal concha – standard instrument - measuring error in mm	Nasal tip – catheter – measuring error in mm	Medial angle of the eye – catheter – measuring error in mm	Anterior edge of middle nasal concha – catheter – measuring error in mm
1	0	0	2	6	8	5
2	0	0	0	5	6	4
3	0	0	0	8	4	6
4	0	0	0	5	6	8
5	0	0	0	4	5	6
6	0	0	0	6	4	2
7	0	2	0	7	6	5
8	0	0	0	6	7	6
9	2	0	0	2	5	4
10	0	0	0	4	2	5
mean	0.2	0.2	0.2	4.8	6.0	5.7

sions in the mucosa. Optical navigation was used. During the operation, data from the guide catheter were introduced to navigating device to allow intra-operative navigation. To navigate, standard instruments (suction, indicator) were used. Then, through the Sinus Guide Catheter an optical fibre sinus illumination system was introduced. This system was a guide, and allowed illumination of the sinus. Finally, a sinus balloon catheter (3.5 or 5.0 mm) was introduced, and the ostium was widened (fig. 1).

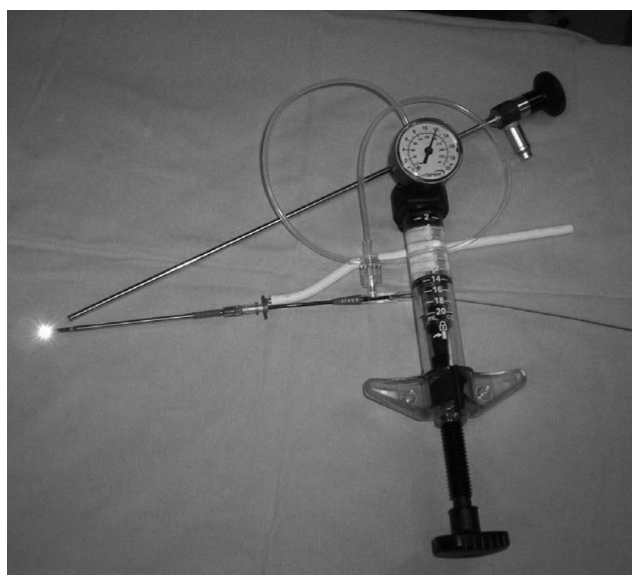


Fig. 1. Balloon sinuplasty devices.

By the use of navigation, the location of the guide catheter was determined, and confirmed by the use of standard instruments. The measurement error was evaluated by identifying such structures as the nasal tip, the medial angle of the eye, and the anterior edge of the middle nasal concha. During the first stage of surgery, a set to locate the natural ostia of the sinuses was used. Then, through the natural maxillary sinus ostium, a guide catheter, with an optical fibre, was introduced. The optical fibre acted as a guide for the balloon. Therefore, the location of the guide catheter was determined by use of the ending of the navigating catheter, standard instruments, and illumination.

**RESULTS**

In the group analysed, there were 10 children, 6 (60%) boys and 4 (40%) girls. The age of the patients varied from 5 to 17 yrs. In the postoperative period (current observation up to 6 months), acute sinusitis was diagnosed in one child. This child recovered after preservative treatment. No adhesions or other disorders were observed in the operated children. In evaluating the measuring error, we have stated that when using standard navigating instruments the mean error was 0.2 mm, and in 10% of measurements the error was 2 mm. Where the guide catheter was used, the parameters having been previously introduced into the navigating system, the mean error fluctuated between 4.8 mm and 6.0 mm. In particular, measurements varied between 2 mm (30% measurements) and 8 mm (30% measurements).

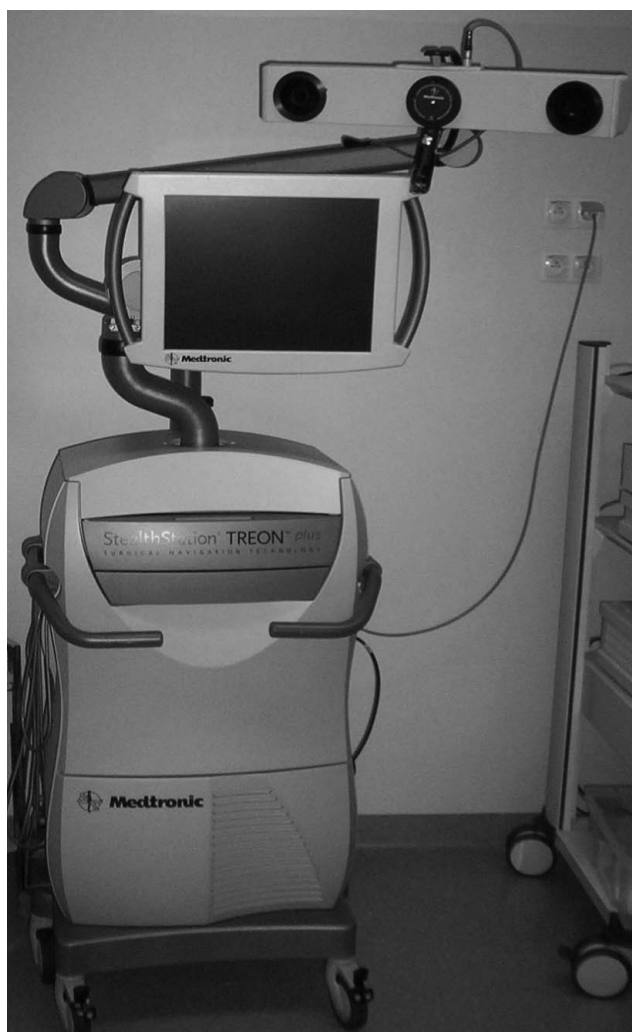

Fig. 2. Intra-operative navigation.

## DISCUSSION

Most authors consider balloon sinuplasty as minimally invasive, and as reducing patient discomfort in the postoperative period. Few observations of postoperative complications involve, amongst others, temporary dysosmia. In our material we have not mentioned such complications. Only a few reports describe the

use of this method in children. From our previous post-operative observations, we can confirm good clinical results using this method (8, 9). Most authors comment favourably on the value of clinical intra-operative navigation. Its range of error is estimated at around 2 mm (10-12) (fig. 2).

In our research, we also evaluated the use of standard navigating instruments, which extend the possibilities of navigation, although the measured error increases in these cases.

## CONCLUSIONS

1. Balloon sinuplasty seems to be the optimal method of treatment for children with stenosis of the natural ostia of the sinus and limited mucous lesions.
2. Intra-operative navigation allows better orientation in the operating area when using balloon sinuplasty, and also allows a decrease in the dose of X-rays in the perioperative period.
3. The use of navigation with standard instruments gives smaller measured error than the use of navigation with instruments additionally introduced into the system. □

## References

1. Stammberger H: The evolution of functional endoscopic sinus surgery. *ENT Journal* 1994; 73, 7: 451-455.
2. Wigand ME: Endoscopic surgery of the paranasal sinuses and interior skull base. Georg-Thieme Verlag Stuttgart 1990.
3. Rettinger G, Gjuric M: Osteoplastic endonasal approach to the maxillary sinus. *Rhinology* 1994; 32(1): 42-44.
4. Chmielik M et al.: Mini FESS in children. *New Medicine* 2004; 3, 62-65.
5. Kennedy DW et al.: *Paediatric Sinusitis*. P.Lusk Raven Press New York 1992, 84.
6. Stankiewicz JA: Paediatric endoscopic nasal and sinus surgery. *Otolaryngol Head Neck Surg* 1995; 113(3): 203-210.
7. Bolger WE, Vaughan WC: Catheter-based dilation of the sinus ostia: Initial safety and feasibility analysis in a cadaver model. *Am J Rhinol* 2006; 20: 290-294.
8. Ramadan HH: Safety and feasibility of balloon sinuplasty for treatment of chronic rhinosinusitis in children. *Ann Otol Rhinol Laryngol* 2009; 118: 161-165.
9. Hassan H, Ramadan, Kevin McLaughlin, Gary Josephson et al.: Balloon catheter sinuplasty in young children. *Am J Rhinol Allergy* 2010; 24, e54-e56, doi: 10.2500.
10. Ewers R, Schicho K, Undt G et al.: Basic research and 12 years of clinical experience in computer-assisted navigation technology: a review. *Int J Oral Maxillofac Surg* 2005; 34 (1): 1-8.
11. Lapeer R, Chen MS, Gonzalez G et al.: Image-enhanced surgical navigation for endoscopic sinus surgery: evaluating calibration, registration and tracking. *Int J Med Robot* 2008; 4 (1): 32-35.
12. Chmielik LP et al.: Usefulness of Intraoperative Navigation In Sinus Operations on Children. *New Medicine* 2008; 3, 12, 77-79.

Received: 28.09.2011  
Accepted: 19.10.2011

Correspondence to:  
\*Lechosław P. Chmielik  
Klinika Otolaryngologii Dziecięcej WUM  
Ul. Marszałkowska 24, 00-576 Warszawa  
tel./fax: +48 22 628 05 84  
e-mail: laryngologia@litewska.edu.pl