

## Acute isolated sphenoid sinusitis in children: a case report and literature review

### Ostre zapalenie zatoki klinowej u dzieci: opis przypadku i przegląd literatury

Department of Pediatric Otolaryngology, Head and Neck Surgery Medical University of Silesia in Katowice, Poland  
Head of Department: Associate Professor Ireneusz Bielecki, MD, PhD

#### KEYWORDS

isolated sphenoid sinusitis, headache, endoscopic transnasal, sphenoidotomy, vision disorders

#### SUMMARY

Acute isolated sphenoid sinusitis in the pediatric population is rare. The final diagnosis is often based on the neurological symptoms due to ongoing intracranial complications. Without proper treatment the disease can lead to serious complications. The sphenoid sinusitis has nonspecific complaints. It is rarely accompanied by the typical symptoms of a rhinitis infection. The main and most common symptoms of acute sphenoid sinusitis are fever and headache. Alarming signs are abnormalities of neurological and ophthalmologic examination. Inflammation of the sphenoid sinus can present visual problems like double vision, limited visual field, impaired visual acuity and even blindness. They require urgent diagnostics, neuroimaging and implementation of appropriate pharmacological and surgical treatment. A normal endoscopic image of the nasal cavities does not exclude sphenoid sinus disease. In the paper the case of 12-year-old girl with vision disturbances and acute sphenoid sinusitis was presented. Nasal endoscopy, neurologic and ophthalmologic examination and neuroimaging were used to confirm the diagnosis of isolated sphenoiditis. The presentation of symptoms, radiological findings, treatment and clinical outcomes were described. Reviewed literature was analyzed.

#### SŁOWA KLUCZOWE

izolowane zapalenie zatoki klinowej, ból głowy, przeznosowa endoskopowa sfenoidektomia, zaburzenia widzenia

#### STRESZCZENIE

Izolowane zapalenie zatoki klinowej w populacji pediatrycznej występuje rzadko. W wielu przypadkach rozpoznanie stawiane jest dopiero po wystąpieniu objawów neurologicznych wskutek powikłań wewnątrzczaszkowych. Nierozpoznane i nieprawidłowo leczone zapalenie zatoki klinowej może doprowadzić do poważnych następstw. Początkowe objawy choroby są mało specyficzne. Najczęściej występują bóle głowy i gorączka. Zazwyczaj nie ma objawów ze strony nosa. Niepokojącymi sygnałami są odchylenia w badaniu neurologicznym i okulistycznym. Zapalenie zatoki klinowej może przebiegać z zaburzeniami wzroku o typie podwójnego widzenia, ograniczenia pola widzenia, osłabienia ostrości wzroku, do ślepoty włącznie. Podstawowe znaczenie w ustaleniu rozpoznania mają badania obrazowe (tomografia komputerowa, rezonans magnetyczny) oraz badanie endoskopowe nosa i nosogardła. Prawidłowy wynik badania endoskopowego jamy nosa nie wyklucza zapalenia zatok klinowych. W pracy przedstawiono przypadek 12-letniej dziewczynki z ostrym, izolowanym zapaleniem zatoki klinowej powikłanym obrzękiem lewej tarczy nerwu wzrokowego. Rozpoznanie ustalono na podstawie badań obrazowych, endoskopii nosa oraz konsultacji neurologicznej i okulistycznej. W pracy opisano przebieg kliniczny powikłań zapalenia zatoki klinowej, proces diagnostyczny, leczenie i jego wynik w odniesieniu do danych dostępnych w literaturze.

## INTRODUCTION

Isolated acute sphenoid sinusitis in the pediatric population is rare. In many reported cases the diagnosis is often based on the neurological symptoms due to intracranial complications (1, 2).

Without proper treatment the disease can lead to serious complications, neurological deficits and even death of the patient. The course of disease can be acute or chronic. The sphenoid sinusitis has nonspecific symptoms. It is not always accompanied by the typical symptoms of a rhinitis infection. The main and most common symptoms of acute sphenoid sinusitis are fever, which occurs in 99-100% of children, and headache – this symptom is present in 82% of patients (1-4). The headache is most often described as retroorbital or in the occipital and parietal region (5-8). Alarming signs are abnormalities of neurological and ophthalmologic examination. They require urgent diagnostics, neuroimaging (CT scan, MRI) and implementation of appropriate treatment (4). We present the case of a 12-year-old girl with headaches and swelling of the left optic nerve disc, whose MRI scan showed acute isolated left sphenoid sinusitis. Inflammation of the sphenoid sinus can present visual problems like double vision, limited visual field, impaired visual acuity and even blindness. Ophthalmic dysfunctions may also result from pathologies of the oculomotor, trochlear, and abducens nerves (3, 4).

## CASE REPORT

A 12-year-old female patient transferred from the neurology department to the Department of Pediatric Otolaryngology Head and Neck Surgery in Katowice because of unusual complaints of headache and a feeling of numbness in the right half of the face for a month. The ophthalmologic examination revealed swelling of the left optic nerve disc.

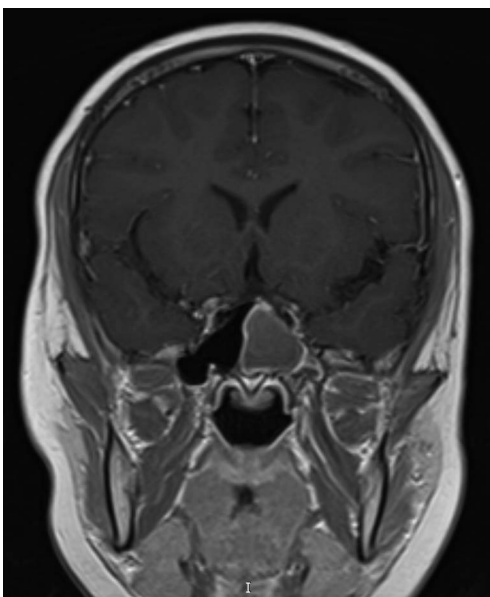


Fig. 1. MRI of the head showing left sphenoid sinusitis

An MRI of the head showed complete opacification of the left sphenoid sinus (fig. 1). After admitting to our department additionally the CT scan of the sinuses was performed (fig. 2). Endoscopy of the nasal cavities showed a bulging of the anterior wall of the sphenoid sinus with yellow translucent sinus contents (fig. 3). An endoscopic sinus surgery

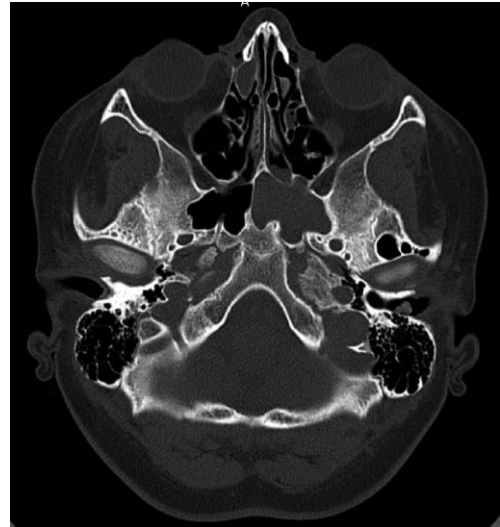

Fig. 2. CT scan - total opacification of the left sphenoid

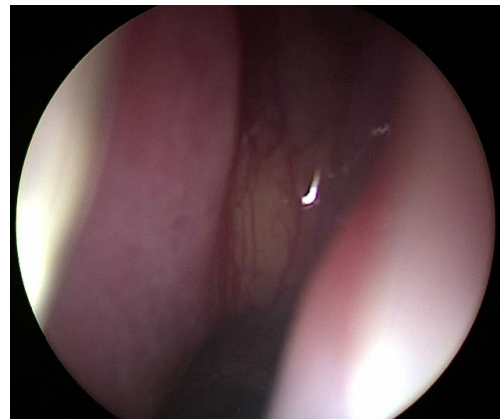


Fig. 3. Endoscopy of the nasal cavities showed a bulging of the anterior wall of the sphenoid sinus with yellow translucent sinus contents

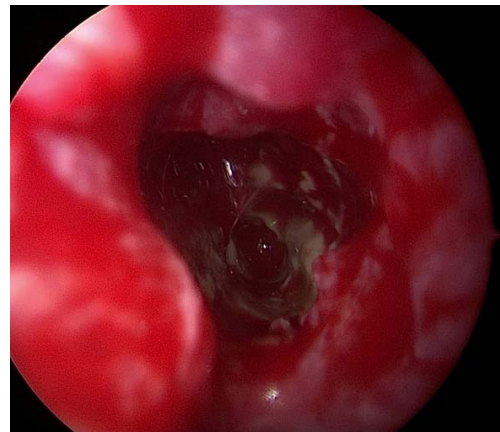


Fig. 4. Content of the cavity of sphenoid after the anterior wall removal

by a trans-septal approach was conducted. The anterior wall of the left sphenoid sinus was removed. Serous, dense masses were present in the cavity of sinus (fig. 4). Using a suction and forceps, the sinus was cleared, making the normal mucosa visible. A smear was taken for bacterial and fungal examinations. The culture grew *Streptococcus epidermidis*. The culture smear for fungal pathogens was negative. Histopathological examination of the collected mucosa showed inflammation with lymphocytic infiltrations. A absorbable dressing was applied. There were no complications in perioperative course. Pharmacological treatment included intravenous ceftriaxone, dexamethasone and intranasal xylometazoline spray. Local nystatin was administered due to post-antibiotic oral and pharyngeal candidiasis. A follow-up ophthalmologic consultation 2 days after FESS revealed blurred outlines of the optic nerve disc (features of edema) without visual acuity impairment. The patient was discharged home on the second day after surgery (hospitalization lasted 4 days).

## DISCUSSION

Acute, isolated sinusitis of the sphenoid sinus is rare and represents about 2-3% of all sinusitis. The sphenoid sinus mucosa is composed of fewer mucus-secreting cells, hence inflammation is less common (6). The main symptoms of acute sphenoid sinusitis are fever above 39 degrees of Celsius, headache and visual manifestations – double vision, impaired visual acuity and limited visual field. The localization of headache is not characteristic – most often the pain is located in the occipital and parietal or retroorbital region. Patients also describe pain at the top of the head, in temporal or frontal area. Often the location of headaches is variable (7, 8). Other rare symptoms include ear ache, neck pain and photophobia. There are no typical, pathognomonic symptoms of acute sphenoid sinusitis. Usually there are no symptoms of rhinitis present (1, 5, 6). In case of the reported patient, the diagnosis was made when swelling of the optic nerve disc was already manifesting. Alleviation of symptoms by symptomatic treatment (analgesics) often delays proper diagnosis. Available painkillers are effective in the early stages of the disease, but have no effect in the advanced phases. The disease can be acute or chronic (5, 6). Onset of acute sinusitis can course with non typical signs and symptoms. Extending the diagnostics to neuroimaging is often based on appearance of neurological or ophthalmic symptoms due to spreading the inflammation to surrounding structures. Predispositions to sinusitis include abnormality of the sinus anatomy, deviated nasal septum, small or abnormally located sphenoid ostium, an enlarged upper or middle nasal turbinate, allergic rhinitis, and nasal polyps (3, 9, 10). Individual variability in the aeration of the sphenoid sinus imposes a different risk of spreading the infection to adjacent structures i.e. the pituitary gland, cavernous sinus, internal carotid artery, pterygospinous canal, palatine ganglion and nerves II, III, IV, VI, V2

and V3 (3, 4, 9, 11). Other risk factors are history of facial trauma, swimming and diving, asthma, immune deficiencies and diabetes (6, 12, 13). For all sinuses, a predisposing factor for the bacterial overgrowth is the dysfunction of the ventilation of the sinus due to its obstructed ostium. This leads to the development of an anaerobic environment facilitating the growth of pathogens (14, 15). Radiologic features of acute sinusitis are demonstrated by marginal thickening of the sinus mucosa, submucosal edema, fluid levels or the presence of air bubbles in sinus lining secretions (9). In a study of chronic inflammatory lesions of the sphenoid sinuses conducted by Massoubre et al. 40% of the subjects had sinus bone wall defects present and 64% of the subjects had radiographic thickening of the sphenoid sinus bone walls. The thickening of the bony walls of the sinus on CT images indicates accompanying inflammation of the periosteum and this correlates with chronic inflammation (16, 17). The acute phase or exacerbation of the chronic stage may be accompanied by fever, runny nose, eyeball pain, postnasal drip, nasal blockage and olfactory dysfunction (10, 15). However, the above symptoms may not be present at all which is due to the deep setting of the sinus in the skull. Basic examination is the evaluation of the nasal cavity with an endoscope. In children, flexible nasofiberscopes are better tolerated. A normal endoscopic finding does not exclude pathology in the sinus cavity (4). CT scan of the sinuses is a good test for evaluating the sinuses and planning endoscopic surgery, but in case of visual disturbances or other neurological symptoms, it is advisable to extend the diagnosis with MRI. The characteristic findings in fungal etiology of sinusitis are microcalcifications in the sinus cavity (11, 17). The first choice treatment is functional endoscopic sinus surgery. There are several endoscopic procedures accessing the sphenoid sinus – trans-ethmoidal, trans-nasal, trans-septal, trans-pterygoidal approaches (3, 4, 18, 19). A study describing the location of the sphenoid sinus ostium was described by Kim et al. in their work on 100 adult cadavers. The natural ostium of the sphenoid sinus is located in adults at an angle of 35.9° at a distance of 56.5 mm from the nasal bridge. This opening occurs 1 cm above and medial to the posterior-inferior pole of the middle nasal turbinate (20). Treatment involves opening and dilating the sinus opening with removal of inflammatory masses from the sinus cavity. Restoration of normal sinus ventilation prevents recurrence of the disease (18, 21). The initial phase of acute sinusitis most often has a viral etiology. Nasal cavity cleansing with saline, anti-inflammatory drugs and intranasal steroids are indicated (21, 22). In cases of acute purulent inflammation, antibiotic therapy should be used. The drug of choice is amoxicillin or cefuroxime. Second-choice antibiotics include amoxicillin with clavulanic acid or levofloxacin. Treatment can be used in combination with clindamycin (22-24). Systemic steroids are recommended for neurological disorders, including visual disturbances (25). In the case described in the publication,

the alarming symptom was swelling of the optic disc on the side of the sinusitis. In a study by Fooanant et al. evaluating sphenoid sinusitis in 1,442 patients visual disturbances were the second most common symptom (after headaches) and occurred in 35% of subjects (25). Isolated sphenoid sinusitis often presents with predominant neurological symptoms and minimal sinus complaints (26-35). Kotowski and Szydłowski described a case of sphenoid sinusitis presenting with dizziness without headache (4). Recurrences of sinusitis are rare and result from blockage of the sinus opening (1, 31). Girls predominate in correlating the disease to sex (22, 28). The case described in this paper also involves

a girl. Despite neurological complications, children most often make a full recovery. The risk of severe intracranial complications is 8.3%. The mortality rate sphenoid sinusitis with complications is estimated at 2.9% (29-35).

## CONCLUSIONS

Isolated sphenoid sinusitis presents with nonspecific symptoms. The diagnosis is most often established on the basis of imaging studies. A normal endoscopic image of the nasal cavities does not exclude sphenoid sinus disease. Sphenoid sinusitis should be considered in the differential diagnosis of atypical headaches.

## CONFLICT OF INTEREST KONFLIKT INTERESÓW

None  
Brak konfliktu interesów

## CORRESPONDENCE ADRES DO KORESPONDENCJI

\*Agata Gierlotka  
Oddział Otolaryngologii z Pododdziałem  
Leczenia Krótkoterminowego  
Górnośląskie Centrum Zdrowia Dziecka  
im. św. Jana Pawła II  
Samodzielny Publiczny Szpital  
Kliniczny Nr 6 Śląskiego Uniwersytetu  
Medycznego w Katowicach  
ul. Medyków 16, 40-752 Katowice  
tel.: +48 (32) 207-19-73  
agierlotka@gczd.katowice.pl

## REFERENCES/PIŚMIENNICTWO

1. Gilony D, Talmi YP, Bedrin L et al.: The clinical behavior of isolated sphenoid sinusitis. *Otolaryngol Head Neck Surg* 2007; 136: 610-615.
2. Güvenç MG, Kaytaç A, Acar GU, Ada M: Current management of isolated sphenoiditis. *Eur Arch Otorhinolaryngol* 2009; 266: 987-992.
3. Massoubre J, Saroul N, Vokwely J-E et al.: Results of transnasal transsphenoidal sphenoidotomy in 79 cases of chronic sphenoid sinusitis. *Eur Ann Otorhinolaryngol Head Neck Dis* 2016; 133(4): 231-236.
4. Kotowski M, Szydłowski J: Isolated Sphenoid Sinus Disease in Children. *Int J Environ Res Public Health* 2023; 20(1): 847.
5. Tan HK, Ong YK: Acute isolated sphenoid sinusitis. *Ann Acad Med Singapore* 2004; 33(5): 656-659.
6. Ruoppi P, Seppä J, Pukkila M, Nuutinen J: Isolated sphenoid sinus diseases: report of 39 cases. *Arch Otolaryngol Head Neck Surg* 2000; 126: 777-781.
7. Ishak NL, Subha ST, Abu Bakar S: Isolated sphenoid sinusitis: A big headache. *Malays Fam Physician* 2019; 14(1): 29-30.
8. McKay-Davies I, Buchanan MA, Prinsley PR: An unusual headache: Sphenoiditis in children and adolescents. *Int J Pediatric Otorhinolaryngol* 2011; 75: 1486-1491.
9. Sethi KS, Choudhary S, Ganesan PK et al.: Sphenoid sinus anatomical variants and pathologies: pictorial essay. *Neuroradiology* 2023; 65(8): 1187-1203.
10. Joshi VM, Sansi R: Imaging in Sinonasal Inflammatory Disease. *Neuroimaging Clin N Am* 2015; 25(4): 549-568.
11. Lawson W, Reino AJ: Isolated sphenoid sinus disease: an analysis of 132 cases. *Laryngoscope* 1997; 107(12 Pt 1): 1590-1595.
12. Karatas A, Is M, Guclu E et al.: Intracranial epidural abscess secondary to isolated sphenoid sinusitis. *Br J Neurosurg* 2007; 21(6): 616-618.
13. Marseglia GL, Pagella F, Licari A et al.: Acute isolated sphenoid sinusitis in children. *Int J Pediatr Otorhinolaryngol* 2006; 70(12): 2027-2031.
14. Klossek JM, Serrano E, Peloquin L et al.: Functional endoscopic sinus surgery and 109 mycetomas of the paranasal sinuses. *Laryngoscope* 1997; 107: 112-117.
15. Charakorn N, Snidvongs K: Chronic sphenoid rhinosinusitis: management challenge. *J Asthma Allergy* 2016; 9: 199-205.
16. Lui YW, Dasari SB, Young RJ: Sphenoid Masses in Children: Radiologic Differential Diagnosis with Pathologic Correlation. *AJNR Am J Neuroradiol* 2011; 32(4): 617-626.
17. Nardi C, Maraghelli D, Pietragalla M et al.: A practical overview of CT and MRI features of developmental, inflammatory, and neoplastic lesions of the sphenoid body and clivus. *Neuroradiology* 2022; 64(8): 1483-1509.
18. Wang PP, Ge WT, Ni X et al.: Endoscopic Treatment of Isolated Sphenoid Sinus Disease in Children. *Ear Nose Throat J* 2019; 98(7): 425-430.
19. Elhamshary AS, Romeh HE, Abdel-Aziz MF, Ragab SM: Endoscopic approaches to benign sphenoid sinus lesions: development of an algorithm based on 13 years of experience. *J Laryngol Otol* 2014; 128(9): 791-796.
20. Kim HU, Kim SS, Kang SS et al.: Surgical anatomy of the natural ostium of the sphenoid sinus. *Laryngoscope* 2001; 111(9): 1599-1602.

21. Yu H, Li H, Chi F et al.: Endoscopic surgery with powered instrumentation for isolated sphenoid sinus disease. *ORL J Otorhinolaryngol Relat Spec* 2006; 68(3): 129-134.
22. Small CB, Bachert C, Lund VJ et al.: Judicious antibiotic use and intranasal corticosteroids in acute rhinosinusitis. *Am J Med* 2007; 120(4): 289-294.
23. Anon JB: Acute bacterial rhinosinusitis in pediatric medicine: current issues in diagnosis and management. *Paediatr Drugs* 2003; 5 Suppl. 1: 25-33.
24. Dzierżanowska-Fangrat K: Przewodnik antybiotykoterapii. Alfa-Medica Press, Bielsko-Biała 2022: 24-26.
25. Fooanant S, Angkurawaranon S, Angkurawaranon C et al.: Sphenoid sinus diseases: a review of 1,442 patients. *Int J Otolaryngology* 2017; 2017: 9650910.
26. Elden LM, Reinders ME, Kazahaya K, Tom LW: Management of isolated sphenoid sinus disease in children: a surgical perspective. *Int J Pediatr Otorhinolaryngol* 2011; 75(12): 1594-1598.
27. Eweiss A, Mukonoweshuro W, Khalil HS: Cavernous sinus thrombosis secondary to contralateral sphenoid sinusitis: a diagnostic challenge. *J Laryngol Otol* 2010; 124(8): 928-930.
28. Bizzoni A, Villaret AB, Lombardi D: Isolated sphenoid inflammatory diseases associated with visual impairment: 15-year experience at a single institution. *Rhinology* 2011; 49: 202-206.
29. Bielecki I, Gierlotka A, Cofała M: An intracranial complication of acute isolated sphenoid sinusitis. *Int J Otorhinolaryngol* 2013: 125-127.
30. Adame N, Hedlund G, Byington CL: Sinogenic intracranial empyema in children. *Pediatrics* 2005; 116(3): 461-467.
31. Olina M, Quaglia P, Stangalini V et al.: Acute complicated sphenoiditis in childhood. Case report and literature review. *Minerva Pediatr* 2002; 54: 147-151.
32. Germiller JA, Monin DL, Sparano AM et al.: Intracranial complications of sinusitis in children and adolescents and their outcomes. *Arch Otolaryngol Head Neck Surg* 2006; 132(9): 969-976.
33. Xiao F, Tseng MY, Teng LJ et al.: Brain abscess: clinical experience and analysis of prognostic factors. *Surg Neurol* 2005; 63(5): 442-449.
34. Moonis G, Granados A, Simon SL: Epidural hematoma as a complication of sphenoid sinusitis and epidural abscess: a case report and literature review. *Clin Imaging* 2002; 26(6): 382-385.
35. Tshifularo M, Monama GM: Complications of inflammatory sinusitis in children: institutional review. *South African Family Practice* 2006; 48: 16-19.

**submitted/nadesłano:**

1.02.2023

**accepted/zaakceptowano do druku:**

22.02.2023